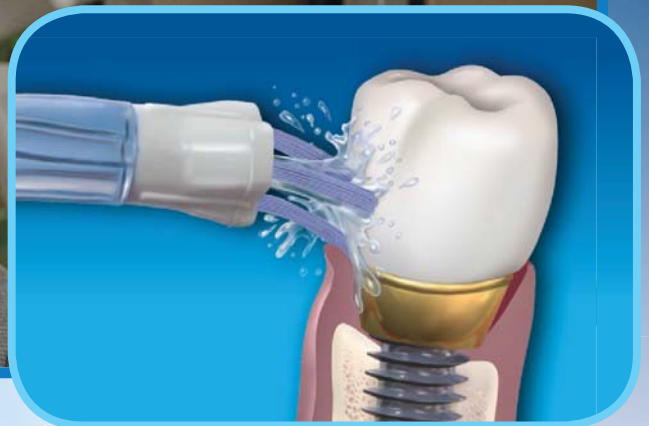



Dr. Michael Tischler



Treatment Planning for Implant Dentistry:

A General Dentist's Guide to Obtain Implant and Soft Tissue Success





Author's Biography:

Dr. Michael Tischler received his DDS degree from the Georgetown University School of Dentistry in 1989. He is a diplomate of the American Board of Oral Implantology/Implant Dentistry, a diplomate of the International Congress of Oral Implantology, a fellow of the Academy of General Dentistry, a fellow of the Misch International Implant Institute, and a fellow of the American Academy of Implant Dentistry. Dr. Tischler has lectured to his colleagues across the United States and Canada on the principles of implant dentistry and bone grafting. He has also been widely published. Dr. Tischler is in private practice in Woodstock, NY, and can be reached through his website at www.tischlerdental.com or at mt@tischlerdental.com.

Disclosure Statement:

Dr. Tischler received an honorarium from Water Pik, Inc.

Course Objective:

To provide the learner with a process for treatment planning dental implants with an emphasis on the health of the surrounding soft tissue. Six areas of treatment planning will be discussed: prosthetic options, health history and clinical data, cone-beam computerized tomography, implant and abutment design, surgical strategies, and oral hygiene for maintenance and daily homecare.

Learning Outcomes:

- Explain the importance of treatment planning for dental implants while considering the issues surrounding soft tissue health.
- Identify the prosthesis options available and how they relate to the surrounding soft tissue, esthetics, and function of the patient.
- Explain how the patient's medical and dental history and clinical data impact implant success.
- Discuss the importance of cone-beam CT and how it is an integral part of the dental implant treatment planning process.
- Recognize how implant and abutment design is related to soft-tissue health.
- Identify key surgical principles that will allow for soft-tissue success with dental implants.
- Recommend the appropriate dental hygiene methods that will maintain the success of soft tissue around dental implants.

INTRODUCTION

According to the American Academy of Implant Dentistry, more than 30 million Americans are missing all their teeth in one or both arches and 15 million have crown and bridge replacements for missing teeth. It is estimated that 3 million people have at least one implant and that number grows by an average of 500,000 each year.¹

The capability to replace missing teeth with dental implants has reached a level of predictability; with long-term success rates of over 95%.² Implant success is multifaceted beginning with a hierarchy of steps that include evidence-based treatment planning, precise surgical execution, and a prosthetic replacement that is esthetically pleasing. Integral to the success of implants is the architecture and health of the soft tissue. The gingival tissue creates a seal around the implant that, when healthy, can be cleaned easily to prevent mucositis and peri-implantitis. At the end of treatment, optimal oral hygiene is critical and the responsibility of the patient and clinician. This course will discuss six key steps for implant placement (Table I).

Table I: Hierarchy of steps for treatment planning

1. Choosing the replacement prosthesis
2. Evaluating health history, clinical assessment, and patient values
3. Obtaining images for diagnosis and treatment
4. Implant and abutment design considerations
5. Surgical strategies at implant placement
6. Hygiene for dental implant maintenance

STEP I: CHOOSING THE PROSTHESIS

You may think discussing the medical and dental history is the first step. However, a good way to get to know the patient is by having a discussion about what they see as the final outcome; what do they want to see when they look in the mirror and smile. That starts with a discussion about the final prosthesis and involves educating the patient about the options appropriate for their particular situation and listening to the patient about their needs, values, and expectations.³

Educating the patient may include demonstration models, diagrams, photos of previous cases, and/or animations of various final implant prosthetics (Figure 1). Computer-based education programs are available that clearly describe and show options for the patient. The available alternatives—non-implant options—should also be discussed. It is the dentist's role to educate patients so they can make an informed decision based on their personal needs and values.

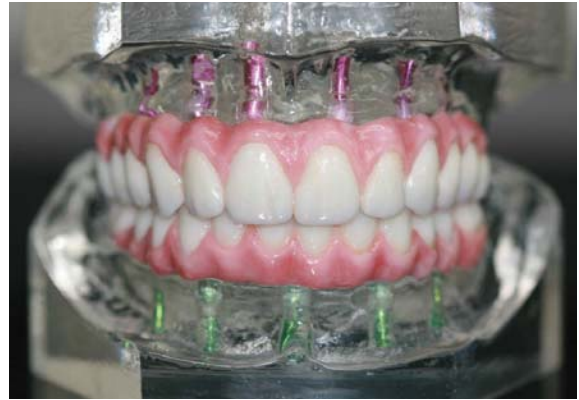

Figure 1: Example of a demonstration model for patient education.

This is important on many levels in the treatment-planning sequence but is an integral part of the informed consent documentation. The differences between a removable prosthesis and a fixed prosthesis is most important when replacement of a full arch of missing teeth is being planned.⁴

Once alternatives have been presented, questions about their needs and preferences should be discussed.⁵ A patient's lifestyle and occupation may help curtail a prosthetic choice. For instance, if a patient is missing all of his or her maxillary teeth, the options presented might be a denture, an implant supported bar overdenture, an implant-only supported overdenture, an implant-supported hybrid bridge, or an implant-supported cement or screw retained bridge (Figures 2a-c). A patient who travels often or is a public speaker may prefer a plan that involves fewer visits and a non-removable prosthesis with less palatal coverage. A woodwind musician or singer would probably prefer a fixed prosthetic rather than a removable prosthetic. Listening to a patient might also provide clues to his or her financial situation even if they do not tell you outright or perhaps they don't value esthetics as much

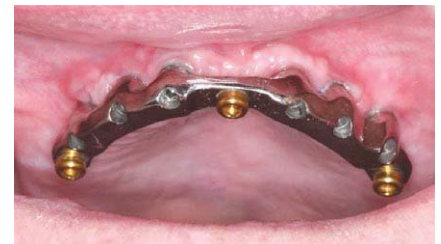

Fig 2a: Support for a bar over denture

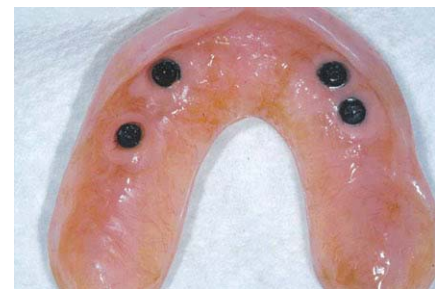

Fig 2b: Non splined over denture

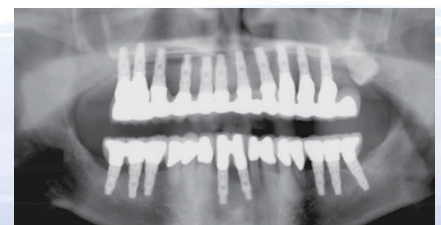


Fig 2c: Radiograph of a cement retained implant bridge

as function. This will help prioritize choices that fit their current situation. Each option has different number of appointments, provisional steps, and length of treatment.

Lastly, the conversation can determine if the patient will be compliant with a personal oral hygiene routine. There are patients who will never be disciplined enough to perform the required hygiene maintenance for a fixed implant supported bridge.⁶ As a result, the treatment plan for a more easily cleaned removable implant-supported prosthesis might be a better choice. If a patient is not going to be compliant, then the soft tissue around the dental implant could become problematic and increase the risk of implant failure. Compliance by a patient with dental implants not only involves personal home care but also a professional evaluation and maintenance appointments which can be three to four times a year.

STEP 2: EVALUATING HEALTH HISTORY AND CLINICAL ASSESSMENT

Health History: The next step is to gather physical information about the patient.⁷ This includes a medical history, dental charting, complete periodontal examination, documentation of tissue architecture, and assessment of the lip support, smile line, dental musculature, TMJ, and bite relationship.

The patient's medical history helps determine if the patient is a suitable candidate for dental-implant surgery.⁸ Contraindications to implant surgery include any uncontrollable systemic disease, pregnancy, uncontrolled psychological disorders, or uncontrolled drug or alcohol use. Considerations to implant surgery include smoking status, surgeries to the head and neck, radiation therapy or other cancer treatments, patient's age and nutritional status, and diseases of the salivary glands (Table II).⁹ Significant medical findings may require a consultation and subsequent medical clearance from the patient's physician. The patient interview can offer abundant information regarding the patient's medical history that is not always evident on the history form. Observation of the patients, pallor, mannerisms, and gait can offer clues to health. This is a good time to talk with a patient who smokes and find out if they are ready to quit. This is a significant life style change and

Table II: Considerations & Contraindications for Implant Surgery

- Uncontrolled systemic disease
- Head & neck radiation therapy
- Age & nutritional status
- Diseases of the salivary glands
- Uncontrolled psychological disorders
- Smoking
- Pregnancy
- Uncontrolled drug or alcohol use

is not easy for many individuals. A baseline blood pressure should be taken at the medical history visit, and patients with a systolic pressure over 140 mm and a diastolic pressure over 90 mm should be referred to their physician for evaluation (Table III).

Table III: Blood Pressure Categories Defined by the American Heart Association¹⁰

Blood Pressure Category	Systolic mm Hg (upper #)		Diastolic mm Hg (lower #)
Normal	less than 120	and	less than 80
Prehypertension	120 - 139	or	80 - 89
High Blood Pressure (Hypertension) Stage 1	140 - 159	or	90 - 99
High Blood Pressure (Hypertension) Stage 2	160 or higher	or	100 or higher
Hypertensive Crisis (Emergency care needed)	Higher than 180	or	Higher than 110

Clinical Assessment:
Comprehensive hard and soft tissue charting is a critical part of the data-gathering process and offers many clues to clinical success for implants and bone grafting.

Documentation of a patient's present dental restorations, mobile teeth, and caries can help in deciding whether a tooth can be saved. Periodontal probing and bone-sounding can offer information on the long-term prognosis of teeth or if periodontal therapy is needed. Bone sounding allows the clinician to map out the osseous support of a tooth. Probing a tooth and an assessment of soft-tissue architecture can also indicate the risk for recession and loss of papillae after a tooth extraction. For instance, if a tooth has thin surrounding gingival biotype, high-scalloped gingival form, and a low osseous crest, the risk for papillae loss after tooth extraction is higher. If a tooth has thick surrounding tissue biotype, flat-scalloped gingival form, and a high osseous crest, there is a lower chance of losing the papillae after an extraction.¹¹ The measurement and documentation of the amount of keratinized tissue is another important component to implant success.¹² Studies show that the presence of keratinized tissue around implants is associated with healthy soft and hard tissue and may reduce the risk of peri-implantitis.¹³

The soft tissue around an implant exhibit similar histological, sulcular and junctional epithelial zones as found with a natural tooth. Teeth have more connective tissue which contains fibers

perpendicular to the root and are imbedded in the cementum, whereas implants have less connective tissue and parallel or oblique fibers.¹⁴ This is a crucial concept to understand when attempting to create implant health. The zone of tissue creates a seal or protective cuff around the neck of the implant. One would assume that the more keratinized tissue around an implant the healthier the peri-implant tissue. A review of the literature showed that when groups of subjects with implants were compared based on clinical parameters, there was a statistically significant better result when there was more keratinized tissue but the quantitative differences were small. Some patients will benefit from more keratinized tissue and others may not. The problem lies with knowing which patient will benefit.^{15,16}

Smile Line and Lip Support: Another step in assessing a patient is to document their smile line and examine their lip support. This is extremely important when treatment planning an edentulous maxillary arch.¹⁷ The smile line and lip support required will help determine the type of prosthesis to be used. For instance, a patient who has worn a maxillary denture for many years may have lost bone along the maxillary ridge. When there is substantial bone loss in the maxillary anterior region, an implant-supported overdenture or hybrid type fixed bridge may be the only choice for the patient due to the lip support offered.¹⁸ The gingival height and smile line are also important when one or more anterior teeth are to be replaced. Individuals with a high smile line often require bone and soft tissue grafting to provide a more exacting gingival margin (Figure 4). Photographs and measurements with a probe are recommended ways to document the esthetic criteria. This is a crucial step for dental implant success in the esthetic zone.

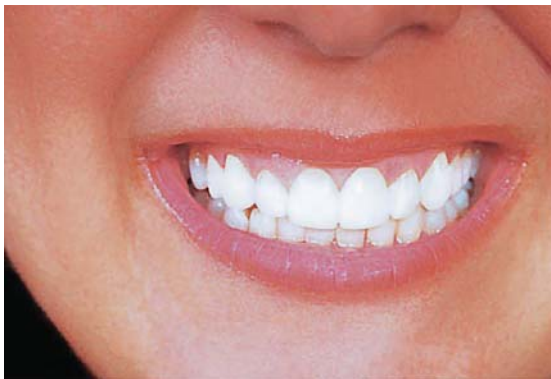

Figure 4: A high smile line that shows the junction between the tooth and gingival tissue.

**Occlusal Relationship:
Assessment of a patient's bite
relationship, TMJ, and musculature
may be the most important
determinant of implant success.¹⁹**

The health of a dental implant is determined by the physics equation $F=S/A$, force equals stress divided by area. When there is too much occlusal stress on a dental implant, there will be bone loss at the crestal area of the implant leading to peri-implantitis and possible implant mobility and loss. Too much stress on an implant could also lead to prosthetic failures, such as screw loosening, porcelain fracture, and even implant fracture. The importance of developing an occlusal scheme that reduces stress on the implants cannot be over-emphasized. It is beyond the scope of this article to address the various occlusal theories available.²⁰

The clinician must also evaluate the patient for patterns of bruxism and clenching.²¹ Para-functional activity by a patient has been shown to be a determining factor in early implant failure.²² Some signs of para-function include enlarged masseter and other muscles of mastication, soreness of the muscles of mastication to palpation, severe or moderate tooth wear, cervical abfraction, mobile teeth, and cracked or fractured teeth.²³ TMJ abnormalities could also indicate para-functional activity. Patients with para-functional complications need to be treatment-planned accordingly which may include; increase in the number of implants, longer and wider implants, and intervention that may minimize the consequences of the para-function. These changes will create more surface area to decrease stress, as dictated by the $S=F/A$ formula. Patients should also be treatment-planned for a night guard after dental implants are placed.

Study models can show occlusal interferences, bite classification, and wear marks. Inter-arch space can also be determined and if there is room for the proposed prosthetic. For the most accurate analysis, a face bow is recommended when obtaining the bite registration and study models.

STEP 3: OBTAINING IMAGES FOR DIAGNOSIS AND TREATMENT

Radiographic analysis and diagnosis for implant placement can be obtained using periapical, panoramic, and cephalometric radiographs, and/or computerized tomography.²⁴ Computerized tomography (CT) use is increasing and offers multiple three-dimensional views that correlates with correct implant size and positioning, size.²⁵ A panoramic X-ray is useful to gauge patient eligibility but additional images are needed if treatment is accepted.

Computerized tomography (CT) produces reconstructed radiological slices called voxels. A cone-beam CT (CBCT) has a source that is designed to target the head and neck. The CBCT produce digital-image communication in medicine (DICOM) data. The CBCT information is analyzed through software programs, which read the DICOM data and produce an image with four different views of the jaw; a cross sectional view (buccal-lingual slice), axial view (mesial-distal slice), panoramic view, and 3D

view. As the views are manipulated in the software program, all views are correlated together, in real time. The end result is an interactive simultaneous four window view that allows for ideal dental implant placement and bone graft planning (Figure 5).

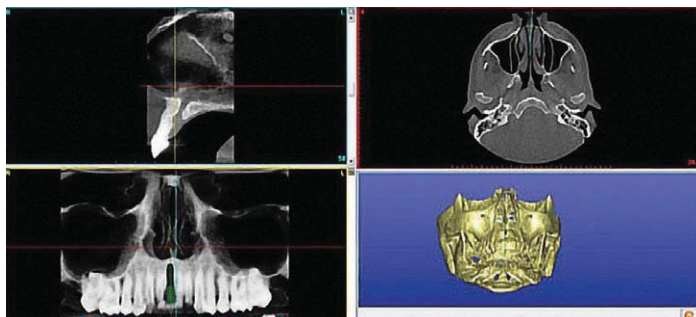


Figure 5: Cross sectional, axial, panoramic, and 3-dimensional views from a CBCT scan.

CBCT machines are available for private dental office use, and in many ways, resemble a panoramic X-ray machine, including both size and simplicity of use.²⁶ Resources are available to support or train dentists who have not worked with this technology. Some radiology imaging companies will guide a clinician through interpretation of the CBCT data and planning for an implant case. This can be done through a live online meeting, without the need to purchase software, or the knowledge of how to use it. These companies will also provide a radiology report of the patient's scan by an oral maxillo-facial radiologist. Some companies provide a service that will bring a mobile CBCT unit to the patient's home or the dentist's office. Additionally, there are stand-alone facilities available that provide CBCT.

A CBCT scan offers pertinent information and accuracy for planning dental implant placement but is more advantageous when the CBCT scan includes the patient's prosthetic end-position.²⁷ This requires a radiographic template and involves a pre-prosthetic workup to create an appliance with the correct esthetic, phonetic, and occlusal criteria that the patient wears during the scan.

On the CBCT-planning software program, implants can be virtually placed on the screen in desired positions. Once the position of the dental implant can be seen relative to the final prosthetic end result, the current status of the bone position can be put in perspective to where the implant will be placed. This allows the clinician to determine if the original bone height will support the desired prosthetic end position or if bone grafting is needed. Having the prosthetic end a CBCT program also allows planning for placement of a dental implant in three orientations.

Mesial-Distal Positioning: The spacing of implants is important with respect to soft tissue health. If dental implants are too close together, or too close to an adjacent tooth, the blood supply

is diminished which could lead to bone loss, tissue loss, and a variety of esthetic and functional problems. A least-position of 3 mm of space between adjacent implants and 2 mm between an implant and adjacent tooth is recommended.²⁸ This helps plan for the correct number of implants to support a determined prosthesis.

Coronal-Apical Position: This view provides coronal or apical position relative to the prosthesis. If an implant is too deep into the tissue, the hygiene of the implant will be negatively affected and soft tissue problems might ensue. If the implant is too coronal, the prosthetic space might not be adequate for the final restoration. Utilizing the data from a CBCT, the bone level apically or coronally to the final prosthetic end position can be seen.

Buccal-Lingual Position: The buccal or lingual position is important for two reasons; one is related to forces on the implant and the other is related to soft tissue health. If the implant is angled too far buccal or lingual, the forces on the implant will be greater. Too much of an angle either way can create a poor emergence profile with the final prosthesis and make oral hygiene difficult.

Once a final plan is determined, the CBCT data can be used to create a surgical guide. A surgical guide is CAD-CAM-milled, based on the information from the CBCT software plan.²⁹ This combination of digital planning and the creation of a surgical guide create the ultimate in safety and precision in dental implant surgery. The surgical guide will navigate the implant drills through narrow tubes to replicate the plan created based on the prosthetic end result.

STEP 4: IMPLANT AND ABUTMENT DESIGN CONSIDERATIONS

The design of the implant body and abutment is a treatment-planning choice by the dentist that can have ramifications on implant success. There are many companies worldwide that provide implant fixtures varying in design and material. Titanium implant fixtures have achieved a high success rate over the years due to improvements in thread designs, abutment connections, and a better understanding of bone science.³⁰ For the purposes of this article, the design choices of the crestal area of a dental implant will be addressed. The crestal area is where the stress of a dental implant is most focused and the soft tissue is most affected.³¹

One basic concept relating to soft-tissue health around an implant is that the soft tissue is healthier adjacent to a polished surface than a rough surface. A polished surface has less adherence of bacteria and allows for better oral hygiene maintenance. Laser-etched surfaces have also shown promising results with respect to

soft tissue health at the crestal area of an implant.³² Bone, on the other hand, is healthier around a roughened surface that allows osteoblasts to approximate to the implant. An implant design that has 2–3 mm of a polished collar is ideal because it mimics the 2–3 mm of free gingiva seen in a healthy periodontal situation. If an implant is placed too deep into the bone and there is too much tissue above it, there is an increased risk of peri-implant disease. There are soft-tissue grafting or tissue-reduction procedures to create an ideal soft-tissue host site for a dental implant.

Another consideration is the size of the implant. If an implant is too wide, the buccal bone can become too thin and the chances of bone loss increase. If bone loss increases, the likelihood of soft-tissue recession increases, allowing esthetic and clinical negative consequences.³³ By having the exact bone width information available on the CBCT, an implant size that allows adequate buccal bone can be planned.

The abutment of a dental implant can also affect the soft tissue formation and the emergence profile.³⁴ Various abutments are available for dental implants, ranging from stock abutments, stock-esthetic abutments, custom-cast abutments, and custom-milled abutments (Figure 6). Custom abutments offer the best strategy for the formation of an ideal emergence profile and soft tissue health around a dental implant.³⁵ Once an accurate impression is taken of a dental implant the dental laboratory can create a custom abutment from a soft-tissue model. A milled titanium abutment offers the advantage of being solid metal with no porosity and increased strength versus a cast metal abutment. Milled zirconia abutments offer ideal esthetics due to their light color, but they are not as strong as a metal abutment.³⁶



Figure 6: Custom implant abutments can offer ideal retention and emergence profile formation.

STEP 5: SURGICAL STRATEGIES AT IMPLANT PLACEMENT

There are techniques that improve soft-tissue health during implant placement and uncover. The first step is to decide if the implant will be placed as a one- or two-stage procedure.³⁷ The benefits of a one-stage procedure are; no need for a second uncover surgery, earlier emergence profile formation with healing cap or provisional, shorter treatment time, and occasionally the immediate placement of the provisional tooth at the time of surgery. A two-stage approach is when the implant is placed under the tissue for a healing period. This is indicated when bone density is soft and will not support good initial implant stability at placement, a removable provisional prosthesis will put undue stress on the dental implant when substantial bone is needed to be grafted, or when simultaneous soft-tissue grafting is needed to create an improved soft-tissue architecture.³⁸

At the uncover of a two-stage implant, the surgeon has the chance to improve the soft tissue around the implant(s). This can be accomplished in one of four ways. The first option is to move the tissue covering a dental implant and re-position it around a healing cap or provisional restoration.³⁹ By doing this, the clinician can maintain keratinized tissue that is there or move keratinized tissue toward the implant. If a provisional restoration is used to create an emergence profile the surface must be smooth. Once the tissue heals, an impression of the provisional can be taken so a dental laboratory can copy the shape. A removable flipper type of provisional is not as proficient in creating an emergence profile, as is a fixed restoration due to its constant movement and may cause damage to the implant or implant site. The second option to improve the surrounding soft tissue is to place a contoured healing abutment or provisional restoration that forms an emergence profile that can form and guide the tissue.⁴⁰ The third option to improve soft tissue is to do a connective tissue graft simultaneous with uncover. The last option is to do tissue reduction. This is often the case on the palatal area of the maxillary arch where there is abundant dense tissue that impedes on the abutment seating or impression coping.

STEP 6: HYGIENE FOR DENTAL-IMPLANT MAINTENANCE

If the above steps are followed then the environment is ideal for the patient and dental professional to maintain the soft tissue around the implant and prosthesis. This is a team effort between the patient and the dental office. Everyone in the office should be familiar with the hygiene protocol and be a part of educating and motivating the patient; albeit the primary responsibility will fall on the hygienist, dentist and dental assistant. The dental team's

goal is to find the right regimen for each patient that is realistic, repeatable, and effective.⁴¹

Implants have been placed for decades but the research on effective methods of oral hygiene are lacking. To date, recommendations are based on the research available, expert opinions and experience. It is not appropriate to assume that what works for natural teeth will work with implants.

Professional Oral Hygiene

Implant patients need continued care similar to other patients. Many implant patients are also periodontal patients and intervals between visits will be similar (3 – 4 months). Ultrasonic, piezo and hand scalers are used but have special tips to prevent scratching the implant surface. Ultrasonic and piezo scalers are used with light pressure and copious irrigation. The inserts are covered with a plastic tip or come with resin tips.⁴² Hand instruments are manufactured with plastic tips (resin), which are changeable, carbon resin tips which can be sharpened, and titanium tips.⁴³

There are different opinions regarding probing implants; some feel it is necessary to evaluate disease, others feel it can negatively impact the seal around the implant.⁴⁴ Which probe to use is also debated with some using a plastic probe and others a metal probe but all recommend gentle probing.⁴⁵ Research supports gentle probing under the appropriate clinical conditions being careful not to disrupt the biological seal.⁴⁶ It is important to angle the probe to compensate for the shape of the prosthesis which in some cases may prohibit effective probing. Probing should be avoided in the first 3 months after placement to allow for complete osseous integration.^{47,48} It is good to get a baseline measurement but it may not be necessary to probe routinely in healthy individuals with excellent oral hygiene. Interpretation of probe readings is not as important as bleeding on probing. Measurements of 3 mm and up to 5 mm may be indicative of health.⁴⁸

Daily Oral Hygiene

The most important component of oral hygiene is the daily routine performed by the patient.

This must be simple yet effective to promote adherence over time. Toothbrushes help clean the supragingival biofilm. There are many designs that can help access areas and sometimes a little imagination is needed. Power toothbrushes have been shown to be safe with implants (Figure 7).⁴⁵ With natural teeth, the next step is interdental cleaning. However, this depends on the type

of prosthesis whether it is a single replacement, over denture, or fixed hybrid bridge. Interdental brushes, floss, wood sticks can all be used. However, getting back to a key point, it must be realistic, consider if the patient can use the product effectively?

One preferred method to clean implants is a Water Flosser. A Water Flosser directs pulsating water to any area around the implant and prosthetic. It is easy to use and has been shown to be safe with implants (Figure 8).^{50,51} Additionally, it will not scratch the implant or prosthetic replacement which is a concern with some interdental brushes. Some offices recommend rinsing with an antimicrobial such as essential oil or chlorhexidine. One study evaluated using a dilute solution of chlorhexidine (0.06%) in a Water Flosser and compared it to rinsing with 0.12% CHX. The Water Flosser group was more effective in reducing plaque and gingivitis and also had significantly less stain than the rinsing group.⁵⁰



Figure 7: Waterpik® Sensonic® Professional Plus Toothbrush includes a standard, compact, and interdental brush head.

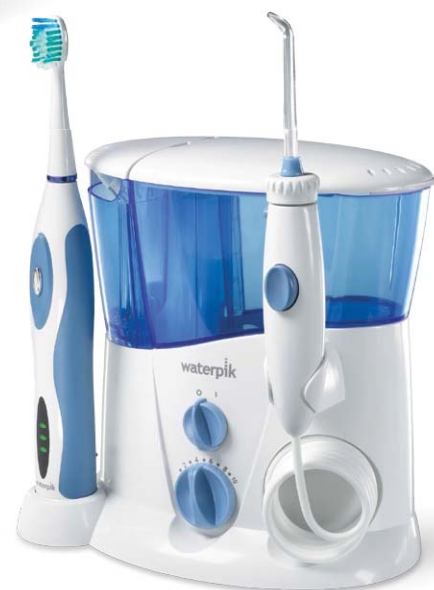

Figure 8: Waterpik® Complete Care combines the benefits of Water Flossing with superior sonic brushing in one unit.

A study conducted at Tufts University compared a Water Flosser to string floss around implants. Both groups used a manual toothbrush twice a day and either the Water Flosser with a special implant tip (Plaque Seeker® Tip) and tap water or string floss once a day. The Water Flosser was 145% more effective than string floss for reducing bleeding around implants at 4 weeks.⁵¹

A Water Flosser has been shown to reduce plaque, bleeding, gingivitis, and pro-inflammatory mediators. Some studies have also shown a reduction in pocket probing depth. One of the key benefits of a Water Flosser is the ability to clean into deep pockets that are not accessible by other self-care aids. A Water Flosser has been shown to reach up to 90% of a 6 mm pocket with a subgingival tip (Pik Pocket™ Tip) and from 44% and 71% of pockets 3 mm – 7 mm with a jet tip (Classic Tip).^{52,53} Additionally, it has been shown to remove pathogenic bacteria in pockets up to 6 mm.^{54,56} It is one of the most widely studied self-care products on the market today.

SUMMARY

Treatment planning for dental implants with respect to maintaining the health of the dental implant and the health of the surrounding tissue is a multifaceted process. It starts with knowing what the correct prosthetic end result is for the patient. The next step is to gather clinical data, including the medical history, to tie that into a successful implant surgical procedure that will support the final prosthesis. Utilizing a 3D cone beam CT, the implant placement position of dental implants is planned for the prosthetic end-result. The choice of implant and abutment design is integral to the final prosthetic result and is assisted by the information gained from the CBCT data. Once a plan is created and the implants are chosen, correct surgical techniques, relating to both placement and uncover, are implemented. These surgical techniques are key steps in the long-term success of both the dental implants and supported prosthesis. The real keys to long-term success are the dental hygiene methods performed by both the dental professional staff and the patient at home. Unless the previous treatment-planning steps are correctly performed, implant hygiene will be difficult and frustrating for the dental office staff and patient. Experience and research has shown that the Waterpik® Water Flosser is more realistically performed on a regular basis by a patient compared to floss, and will also offer the most efficacious results to maintain a healthy environment for the implant.

References

1. American Academy of Implant Dentistry. Dental Implant Facts and Figures. Accessed August 23, 2012. www.aaaid-implant.org/about/PressRoom/Dental_Implants_FAQ.html?print=1
2. Roos-Jansaker A-M, Lindahl C, Renvert H, Renvert S. Nine- to fourteen-year follow-up of implant treatment. Part I: implant loss and association to various factors. *J Clin Periodontol* 2006; 33:283-289.
3. Tischler M. Treatment planning implant dentistry: an overview for the general dentist. *Gen Dent* 2010; 58(5):368-374; quiz 375-376.
4. Drago C, Carpentieri J. Treatment of maxillary jaws with dental implants: guidelines for treatment. *J Prosthodont* 2011; 20(5):336-347.
5. Ricciardi MT, Pizzi P. In complex restorative cases, understanding the patient's expectations is the first step. *Compend Contin Educ Dent* 2010; 31(5):380-384, 386, 388.
6. Real-Osuna J, Almendros-Marqués N, Gay-Escoda C. Prevalence of complications after the oral rehabilitation with implant-supported hybrid prostheses. *Med Oral Patol Oral Cir Bucal* 2011; 17(1):e116-121.
7. Garg AK. Current concepts in patient medical history for dental implant surgery. [Interview]. *Dent Implantol Update* 2005; 16(9):57-60.
8. Cochran DL, Schou S, Heitz-Mayfield LJ, Bornstein MM, Salvi GE, Martin WC. Consensus statements and recommended clinical procedures regarding risk factors in implant therapy. *Int J Oral Maxillofac Implants* 2009; 24(Suppl):86-89.
9. Misch CE. Contemporary Implant Dentistry. 2nd ed. St Louis: Mosby Inc.; 1999: 33-62.
10. American Heart Association. Understanding Blood Pressure Readings. www.heart.org/HEARTORG/Conditions/HighBloodPressure/AboutHighBloodPressure/Understanding-Blood-Pressure-Readings_UCM_301764_Article.jsp. Accessed April 22, 2013.
11. Kois JC. Predictable single-tooth peri-implant esthetics: five diagnostic keys. *Compend Contin Educ Dent* 2004; 25(11):895-896, 898, 900.
12. Schrott AR, Jimenez M, Hwang JW, Fiorellini J, Weber HP. Five-year evaluation of the influence of keratinized mucosa on peri-implant soft-tissue health and stability around implants supporting full-arch mandibular fixed prostheses. *Clin Oral Implants Res* 2009; 20(10):1170-1177.
13. Brägger U, Bürgin WF, Hämmerle CHF, Lang NP. Associations between clinical parameters assessed around implants and teeth. *Clin Oral Implants Res* 1997; 12:749-757.
14. Misch CE. Contemporary Implant Dentistry. 2nd ed. St Louis: Mosby Inc.; 1999: 239-241.
15. Kim BS, Kim YK, Yun PY, Yi YJ, Lee HJ, Kim SG, Son JS. Evaluation of peri-implant tissue response according to the presence of keratinized mucosa. *Oral Surg Oral Med Oral Pathol Oral Radiol Endod* 2009; 107(3):e24-28.
16. Greenstein G, Cavallaro J. The clinical significance of keratinized gingiva around dental implants. *Comp Contin Ed Dent* 2011; 32(8):24-32.
17. Bidra AS. Three-dimensional esthetic analysis in treatment planning for implant-supported fixed prosthesis in the edentulous maxilla: review of the esthetics literature. *J Esthet Restor Dent* 2011; 23(4):219-236.
18. Chee WW. Treatment planning: implant-supported partial over dentures. *J Calif Dent Assoc* 2005; 33(4):313-316.
19. Carlsson GE. Dental occlusion: modern concepts and their application in implant prosthodontics. *Odontology* 2009; 97(1):8-17.
20. Fu JH, Hsu YT, Wang HL. Identifying occlusal overload and how to deal with it to avoid marginal bone loss around implants. *Eur J Oral Implantol* 2012; 5(Suppl):S91-S103.
21. McCoy G. Recognizing and managing parafunction in the reconstruction and maintenance of the oral implant patient. *Implant Dent* 2002; 11(1):19-27.
22. Manfredini D, Bucci MB, Sabattini VB, Lobbezoo F. Bruxism: overview of current knowledge and suggestions for dental implants planning. *Cranio* 2011; 29(4):304-312.
23. Lobbezoo F, Van Der Zaag J, Naeije M. Bruxism: its multiple causes and its effects on dental implants - an updated review. *J Oral Rehabil* 2006; 33(4):293-300.
24. Angelopoulos C, Aghaloo T. Imaging technology in implant diagnosis. *Dent Clin North Am* 2011; 55(1):141-158.
25. Ganz SD. Cone beam computed tomography-assisted treatment planning concepts. *Dent Clin North Am* 2011; 55(3):515-536, viii.
26. Orentlicher G, Abboud M. The use of 3-dimensional imaging in dentoalveolar surgery. *Compend Contin Educ Dent* 2011; 32(5):78-80, 82, 85-86.
27. Ganz SD. Restoratively driven implant dentistry utilizing advanced software and CBCT: realistic abutments and virtual teeth. *Dent Today* 2008; 27(7):122, 124, 126-127.
28. Tarnow DP, Cho SC, Wallace SS. The effect of inter-implant distance on the height of the inter-implant bone crest. *J Periodontol* 2000; 71(4):546-549.
29. Ganz SD. Presurgical planning with CT-derived fabrication of surgical guides. *J Oral Maxillofac Surg* 2005; 63(Suppl 2):59-71.
30. Ji TJ, Kan JY, Rungcharassaeng K, Roe P, Lozada JL. Immediate loading of maxillary and mandibular implant-supported fixed complete dentures: a 1- to 10-year retrospective study. *J Oral Implantol* 2011; 38(Special):469-476.
31. Bateli M, Att W, Strub JR. Implant neck configurations for preservation of marginal bone level: a systematic review. *Int J Oral Maxillofac Implants* 2011; 26(2):290-303.
32. Botos S, Yousef H, Zweig B, Flinton R, Weiner S. The effects of laser microtexturing of the dental implant collar on crestal bone levels and peri-implant health. *Int J Oral Maxillofac Implants* 2011; 26(3):492-498.
33. Spray JR, Black CG, Morris HF, Ochi S. The influence of bone thickness on facial marginal bone response: stage 1 placement through stage 2 uncovering. *Ann Periodontol* 2000; 5(1):119-128.
34. Hasan I, Röger B, Heinemann F, Keilig L, Bouraue C. Influence of abutment design on the success of immediately loaded dental implants: Experimental and numerical studies. *Med Eng Phys* 2011; 34(7): 817-825.
35. Schneider A, Kurtzman GM. Computerized milled solid implant abutments utilized at second stage surgery. *Gen Dent* 2001; 49(4):416-420.
36. Klotz MW, Taylor TD, Goldberg AJ. Wear at the titanium-zirconia implant-abutment interface: a pilot study. *Int J Oral Maxillofac Implants* 2011; 26(5):970-975.
37. Tallarico M, Vaccarella A, Marzi GC. Clinical and radiological outcomes of 1- versus 2-stage implant placement: 1-year results of a randomized clinical trial. *Eur J Oral Implantol* 2011; 4(1):13-20.
38. Artzi Z, Nemcovsky CE, Tal H, Weinberg E, Weinreb M, Prasad H, Rohrer MD, Kozlovsky A. Simultaneous versus two-stage implant placement and guided bone regeneration in the canine: histomorphometry at 8 and 16 months. *J Clin Periodontol* 2010;37(11):1029-1038.
39. Misch CE, Al-Shammari KF, Wang HL. Creation of interimplant papillae through a split-finger technique. *Implant Dent* 2004; 13(1):20-27.
40. Lapinski RL, O'Calahan D, Horowitz I, Rosenblum M. Improving the emergence profile of an anterior implant restoration using a custom healing cap and a "double cast" abutment. *N J Dent Assoc* 2007; 78(4):42-43.
41. Vered Y, Zini A, Mann J, Kolog H, Steinberg D, Zambon JJ, Haraszthy VI, DeVizio W, Sreenivasan P. Teeth and implant surroundings: clinical health indices and microbiologic parameters. *Quintessence Int* 2011; 42(4):339-344.
42. Louropoulou A, Slot DE, Van der Weijden F. Titanium surface alterations following the use of different mechanical instruments: a systematic review. *Clin Oral Imp Res* 2012; 23(6):643-658.
43. Kawashima H, Sato S, Kishida M, et al. Treatment of titanium dental implants with three piezoelectric ultrasonic scalers: an in vivo study. *J Periodontol* 2007; 78:1689-1694.
44. Speelman JA, Collaert B, Klinge B. Evaluation of different methods to clean titanium abutments. A scanning electron microscopic study. *Clin Oral Implants Res* 1992; 3:120-127.
45. Matarosso S, Quaremba G, Coraggio F, et al. Maintenance of implants: an in vitro study of titanium surface modifications subsequent to the application to the application of different prophylaxis procedures. *Clin Oral Implants Res* 1996; 7:64-72.
46. Jepsen S, Ruhling A, Jepsen K, Ohlenbusch B, Albers H-K. Progressive peri-implantitis. Incidence and prediction of perimplant attachment loss. *Clin Oral Implants Res* 1996; 7:133-142.
47. Luterbacher S, Mayfield L, Bragger U, Lang NP. Diagnostic characteristics of clinical and microbiological tests for monitoring periodontal and perimplant mucosal tissue conditions during supportive periodontal therapy (SPT). *Clin Oral Implants Res* 2000; 11:521-529.
48. Salvi GE, Lang NP. Diagnostic parameters for monitoring peri-implant conditions. *Int J Oral Maxillofac Implants* 2004; 19(Suppl):116-127.
49. Esposito M, Worthington HV, Thomsen P, Coulthard P. Interventions for replacing missing teeth: maintaining health around dental implants. *Cochrane Database Syst Rev* 2004; (3):CD003069.
50. Felo A, Shibly O, Ciancio SG, Lauciello FR, Ho A. Effects of subgingival chlorhexidine irrigation on peri-implant maintenance. *Am J Dent* 1997; 10:107-110.
51. Magnusson B, Harsono M, Silberstein J, Stark P, Perry R. Water Flosser vs. Floss: Comparing reduction of bleeding around implants. *IADR 2013*, Seattle, WA. Abstract #3761.
52. Braun RE, Ciancio SG. Subgingival delivery by an oral irrigation device. *J Periodontol* 1992; 63(5):469-472.
53. Eakle WS, Ford C, Boyd RL. Depth of penetration in periodontal pockets with oral irrigation. *J Clin Periodontol* 1986; 13(1):39-44.
54. Cobb CM, Rodgers RL, Killoy WJ. Ultrastructural examination of human periodontal pockets following the use of an oral irrigation device in vivo. *J Periodontol* 1988; 59(3):155-163.
55. Drisko CL, White CL, Killoy WJ, Mayberry WE. Comparison of dark-field microscopy and a flagella stain for monitoring the effect of a Water Pik® on Bacterial Motility. *J Periodontol* 1987; 58(6):381-386.

POST TEST COURSE #13-23

Treatment Planning for Implant Dentistry: A General Dentist's Guide to Obtain Implant and Soft Tissue Success

- 1. What is the first step in treatment planning for dental implants?**
 - a. Determining where the force factors on dental implants can be eliminated
 - b. Performing periodontal probing on remaining teeth
 - c. Determining with the patient what the final prosthesis is going to be
 - d. Take a detailed medical history
- 2. What are important steps in the treatment planning process?**
 - a. Asking a patient about their lifestyle
 - b. Educating a patient about what options are available
 - c. Asking a patient about their present home care regiment
 - d. All of the above
- 3. How many fiber groups surround a dental implant?**
 - a. 2
 - b. 4
 - c. 6
 - d. 11
- 4. When evaluating the prospective outcome for implant surgery, which patient factors should be considered?**
 - a. Pregnancy
 - b. Radiation therapy
 - c. Smoking
 - d. All of the above
- 5. Which anatomical situation creates the lowest risk for papillia loss after tooth extraction?**
 - a. Thick surrounding gingival biotype
 - b. High scalloped gingival form
 - c. Low osseous crest
 - d. Thin surrounding gingival biotype
- 6. What signals too much stress on an implant?**
 - a. Prosthetic failure
 - b. Crestal bone loss
 - c. Implant mobility
 - d. All of the above
- 7. Which is not a sign of parafunctional activity?**
 - a. Cracked teeth
 - b. TMJ pain
 - c. Enlarged massater muscles
 - d. Cuspid guidance
- 8. What is the most informative type of radiological diagnosis for implant planning?**
 - a. Panoramic X-Ray
 - b. Peri Apical X-Ray
 - c. Cone Beam CT
 - d. Cephalametric X-Ray
- 9. Which of the four different views on a CBCT offers a buccal/lingual slice?**
 - a. Axial view
 - b. Panoramic view
 - c. Cross sectional view
 - d. 3D view
- 10. What information does a CBCT offer?**
 - a. Buccal/lingual orientation of an implant prior to placement
 - b. Mesial/distal positioning of an implant prior to placement
 - c. Coronal/Apical positioning prior to placement
 - d. All of the above
- 11. The stress around an implant is focused mostly where?**
 - a. The apical area
 - b. The mid section of the implant
 - c. The most outside threads along the implant
 - d. The crestal area of the implant
- 12. Which statement is true about abutments?**
 - a. Zirconia abutments are not esthetic but offer high strength
 - b. Custom cast abutments are the strongest of any abutments available because there is no porosity
 - c. Milled titanium abutments do not offer a good emergence profile
 - d. Milled titanium abutments are the strongest abutments without porosity
- 13. A one stage implant procedure offers all but which advantage?**
 - a. A second uncover surgery
 - b. Earlier emergence profile formation
 - c. The availability of a tooth at the time of surgery
 - d. Shorter treatment time
- 14. How much more effective is a Water Flosser than string floss for reducing bleeding around implants?**
 - a. 108%
 - b. 132%
 - c. 146%
 - d. 174%
- 15. Why is a Water Flosser recommended for implant maintenance?**
 - a. Shown to reduce bleeding
 - b. Better than flossing
 - c. Can clean subgingival area
 - d. All of the above



CE REGISTRATION FORM AND ANSWER SHEET

Course #13-23: Treatment Planning for Implant Dentistry: A General Dentist's Guide to Obtain Implant and Soft Tissue Success

Name: _____

Credentials: _____

Street Address: _____

City: _____

State: _____ Zip: _____

Email: _____ @ _____

Day Phone: _____ Cell or Home Phone: _____

Answer Sheet

Please circle the correct answer for each question.

1.	a	b	c	d
2.	a	b	c	d
3.	a	b	c	d
4.	a	b	c	d
5.	a	b	c	d
6.	a	b	c	d
7.	a	b	c	d
8.	a	b	c	d
9.	a	b	c	d
10.	a	b	c	d
11.	a	b	c	d
12.	a	b	c	d
13.	a	b	c	d
14.	a	b	c	d
15.	a	b	c	d

Course Evaluation

Circle your response: 1 = lowest, 5 = highest

Course objectives were met
1 2 3 4 5

Content was useful
1 2 3 4 5

Questions were relevant
1 2 3 4 5

Rate the course overall
1 2 3 4 5

How did you acquire this course:
Internet DVD Tradeshow CE Handout Other _____

OBTAINING CONTINUING EDUCATION CREDITS

Credits: 3 hours

If you have questions about acceptance of continuing education (CE) credits, please consult your state or provincial board of dentistry.

Directions:

- Fill out the Water Pik CE Registration Form and Answer Sheet.
- Answers should be logged on the answer sheet. Please make a copy of your post-test and answer sheet to retain for your records.
- Only one original answer sheet per individual will be accepted.
- Answers left blank will be graded as incorrect.
- Please fill out the course evaluation portion.
- The post-test may be submitted via mail, fax, or email to:

Water Pik, Inc
 1730 East Prospect Road
 Fort Collins CO 80553
 Attn: Continuing Education Self Study Program
 Fax: 1-970-221-6075
 Email: ce@waterpik.com

Scoring:

In order to receive credit, you must answer 10 of the 15 questions correctly.

Results:

By email: 6 weeks

(Please make sure your email address is legible).

By mail: 8-10 weeks

Questions regarding content or applying for credit?

Contact: Carol Jahn, RDH, MS, by email: cjahn@waterpik.com or phone: 630-393-4623



Academy of General Dentistry Approved
 PACE Program Provider FAGD/MAGD Credit.
 Approval does not imply acceptance by a
 state or provincial board of dentistry or AGD
 endorsement. The current term of approval
 extends from 06/01/2010-05/31/2014.